

# Osteoarthritis and Cartilage



International  
Cartilage  
Repair  
Society



## Immunolocalization of carboxy-terminal type II procollagen peptide in regenerated articular cartilage of osteoarthritic knees after reduction of mechanical stress

H. Kobayashi, T. Saito and T. Koshino

Department of Orthopaedic Surgery, Yokohama City University School of Medicine, Yokohama 236-0004, Japan

### Summary

**Objective:** The purpose of this study was to investigate the immunolocalization of carboxy-terminal type II procollagen peptide (pCOL-II-C) in the regenerated articular cartilage grown 1–2 years after reduction of mechanical stress by correction of varus deformity with high tibial osteotomy (HTO) for knees with medial compartmental osteoarthritis.

**Design:** The series included 24 knees of 16 patients with a mean age of 70 (56–79) years. Synovial fluid and tissue specimens of the regenerated articular cartilage were obtained at the time of plate removal with arthrotomy. Tissue specimens were decalcified and stained with toluidine blue, safranin O, anti-type I and type II collagen and anti-pCOL-II-C. Pineda's histological grading of articular cartilage repair and Okada's grade of immunostaining were employed to assess the regenerated articular cartilage.

**Results:** In knees with regeneration of articular cartilage, there was a positive linear correlation between the grade of immunostaining and the concentration of synovial fluid pCOL-II-C ( $r=0.652$ ;  $P<0.001$ ). Similarly, a positive linear correlation was observed between the grade of immunostaining and the histological grading score ( $r=0.683$ ;  $P<0.001$ ).

**Conclusions:** The immunostaining and synovial fluid concentration of pCOL-II-C decreased in accordance with the progression of articular cartilage regeneration observed after reduction of mechanical stress by correction of deformity with HTO. © 2002 OsteoArthritis Research Society International. Published by Elsevier Science Ltd. All rights reserved.

**Key words:** Immunolocalization, Carboxy-terminal type II procollagen peptide, Articular cartilage regeneration, Mechanical stress.

### Introduction

Osteoarthritis (OA) of the knee is one of the most common joint disorders in the elderly. Varus deformity is frequently seen in knees with late-stage OA. The mechanical stress of weight bearing produces pain and advanced degeneration of the articular cartilage on both the femoral and tibial condyles<sup>1</sup>.

High tibial osteotomy (HTO), which corrects varus deformity to relieve mechanical stress exerted on the articular cartilage, is well known to be one of the most effective surgical procedures. Post-operative realignment of the leg provides relief of pain and a good functional outcome in patients with OA<sup>2</sup>. However, few reports<sup>3,4</sup> mentioned intraarticular changes observed after osteotomy, especially of those in the initially degenerated portions of the articular cartilage. Koshino *et al.* reported that one to two years after initial osteotomy, the most severely degenerative portions of articular surface were completely covered by white, uneven layers of fibrocartilage, with no exposure of the subchondral bone<sup>3,4</sup>.

Articular cartilage is composed of chondrocytes, and its surrounding extracellular matrix consists principally of

collagen and proteoglycans. Type II collagen is the major component of hyaline cartilage, and accounts for up to 90% of the dry weight<sup>5,6</sup>. According to Wada *et al.*<sup>7</sup>, a histological study of regenerated articular cartilage obtained after osteotomy showed different types of cells and staining patterns between the superficial layer with spindle-shaped fibrocartilage-like cells and the middle to deep layers with round hyaline cartilage-like cells. Immunohistochemical staining revealed that antitype I collagen was observed mainly in the superficial layer and antitype II collagen in the middle to deep layers.

Carboxy-terminal type II procollagen peptide (pCOL-II-C) was first reported by Choi *et al.*<sup>8</sup>, who characterized 35,000 molecular weight subunit isolated from growth plates of fetal bovine cartilages. This component has been extracted growth plate cartilage, tracheal and laryngeal cartilage; however, it appears to be absent from adult bone and cartilage<sup>9</sup>. Shinmei *et al.*<sup>10</sup> developed an enzyme immunoassay (EIA) for pCOL-II-C and measured synovial fluid levels of pCOL-II-C in OA, rheumatoid arthritis (RA) and traumatic arthritis. Immunohistochemical study of Nakajima *et al.*<sup>11</sup> demonstrated characteristic localization of pCOL-II-C in different stage of OA and RA cartilage. Recent studies revealed that pCOL-II-C was proven to be a potential marker of type II collagen synthesis *in vivo* as well as *in vitro*<sup>12–17</sup>.

Along these lines, many aspects of pCOL-II-C has become clear. However, little is known about the immunolocalization of pCOL-II-C in the regenerated articular

Received 14 December 2001; accepted 15 July 2002.

Address correspondence to: Hayato Kobayashi, MD, Department of Orthopaedic Surgery, Yokohama City University School of Medicine, 3-9 Fukuura, Kanazawa-ku, Yokohama 236-0004, Japan. Tel.: +81-45-787-2655; Fax: +81-45-781-7922; E-mail; hayato-k@f3.dion.ne.jp

Table I  
Macroscopic grading of articular cartilage degeneration in OA of the knee

Grade	Articular cartilage degeneration*
0	Normal
1	Yellow discoloration
2	Softening and unevenness
3	Fasciculation and attrition
4-a	Erosion
4-b	Ulcer with exposure of subchondral bone
4-c	Eburnation of subchondral bone
5-a	Bone destruction in an area less than 5 mm in depth
5-b	Bone destruction in an area 5 mm or more in depth

\*Modified from the grading system of Outerbridge<sup>18,19</sup>.

Table II  
Staging in regeneration of articular cartilage observed through arthrotomy at removal of a blade plate<sup>4</sup>

Stage	Articular cartilage regeneration
0	No regenerative change
1	Pink and yellowish fibrillation
2	White fibrillation scattering
3	Partial coverage with fibrocartilage
4	Overgrowth of white fibrocartilage
5	Even coverage with white fibrocartilage

Stages 0, 1, 2 and 3 are classified macroscopically into the 'Immature' regeneration group, and stages 4 and 5 'Mature' regeneration group.

cartilage obtained after initial osteotomy. In this study, we attempted to examine the relation between pCOL-II-C staining pattern and the level of synovial fluid pCOL-II-C at different stage of cartilage regeneration, and found marked correlation among them. We confirmed that pCOL-II-C could be a clinically useful marker of type II collagen biosynthesis.

## Methods

### SYNOVIAL FLUID AND TISSUE SPECIMEN PREPARATION

Synovial fluid and regenerated articular cartilage were obtained from knees with OA with the patients' consent. Varus deformity of the knee was corrected by initial HTO, and the internal fixation was removed about 2 years later. The series included 24 knees of 16 patients (13 women, three men), whose mean age was 70.7 (range 56 to 79) years. The mean interval between the two operations was 21 (13–31) months. Arthrotomy was performed at the time of both operations, and the articular cartilage in the weight-bearing portion of the medial tibial condyle was observed and evaluated according to the macroscopic cartilage degeneration grading<sup>18,19</sup> (Table I) and regeneration staging<sup>4</sup> (Table II). Intraarticular findings were recorded and photographed with special work files without fail.

The concentration of synovial fluid pCOL-II-C was measured by sandwich EIA (Teijin Corporation, Tokyo, Japan) proposed by Choi *et al.*<sup>8</sup> and Shinmei *et al.*<sup>10</sup>. Control synovial fluid was taken with patients' consent from seven knees of six subjects (four men, two women) with a mean age of 35.8 (25–48) years, who underwent arthroscopic surgery for meniscal injury or shelf disorder (painful

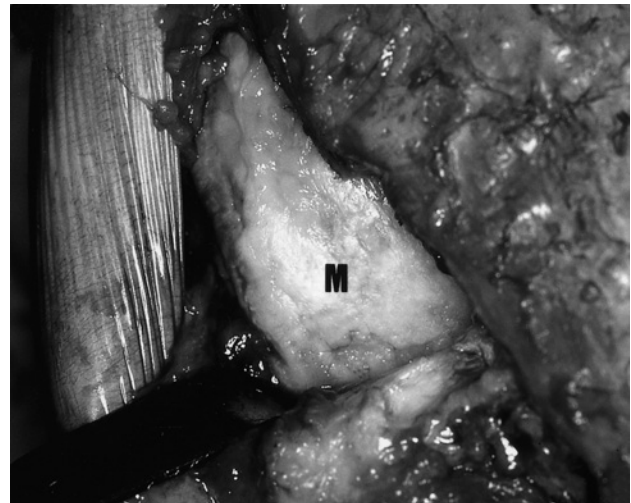


Fig. 1. Photograph of medial femoral condyle (M) of the left knee taken at removal of internal fixation two years after high tibial osteotomy. A white even layer of fibrocartilaginous tissue is observed (stage 5). Full-thickness specimen (5×5×3 mm) was taken from posterior border of previously degenerated portion.

impingement of proliferative plica synovialis medio-patellaris). In all control subjects the articular cartilage was diagnosed as healthy.

Regenerated white fibrocartilaginous tissue (5×5×3 mm, full-thickness specimens) were obtained at the time of blade plate<sup>20</sup> removal from posterior border of previously degenerated portions, which were usually non-weight-bearing when standing straight. The reason for this was to avoid undesirable knee pain when the patients start walking two days after plate removal (Fig. 1). Normal healthy cartilage tissues (controls) were biopsied with patients' consent from four knees of three subjects (two men, one woman) with a mean age of 55.3 (48–63) years, who received above the knee amputation for ischemic necrosis. The specimens were fixed with buffered 10% formaldehyde for 48 h and decalcified with 0.5 M ethylene diamine tetraacetic acid (EDTA), pH 7.5 for 4 weeks, after which they were embedded in paraffin. Serial sagittal sections (5 μm thick) were prepared and initially stained with acidified toluidine blue (1B481, Chroma-Gesellschaft) and safranin O (1B463, Chroma-Gesellschaft; fast green counterstain).

### OPERATIVE PROCEDURES AND POSTOPERATIVE MANAGEMENT

At our institution, more than 1250 patients received HTO since 1968. The operative technique partly followed that described by Bauer *et al.*<sup>2</sup>. The size of a laterally-based wedge of bone to be removed was calculated, to achieve a post-operative femoro-tibial angle of 170° (10° of anatomical valgus angulation)<sup>3,20</sup>. After segmental resection of the mid-fibula, the retinaculum and capsule were released along the medial and the lateral side of the patella and patellar ligament. Then, intraarticular findings were assessed and photographed. The laterally-based wedge was completely removed, following by fixation of the proximal and the distal osteotomy fragments with a blade plate to produce a femoro-tibial angle of 170°. Furthermore, the medial side of the osteotomy site was fixed by a small plate (dual plating fixation). Quadriceps exercise and active motion exercise were begun after a few days, and a

cylinder cast was applied at two weeks, allowing full weight bearing. The plaster was removed after 6 weeks and knee mobilization started.

#### CLASSIFICATION OF CARTILAGE REGENERATION STAGE

For assessment of cartilage repair, we classified established macroscopic cartilage regeneration stages<sup>4</sup> into two groups; one, 'immature' regeneration group including stage 0 (no regenerative change), stage 1 (pink and yellowish fibrillation), stage 2 (white fibrillation scattering) and stage 3 (partial coverage with fibrocartilage); and the other, 'mature' regeneration group including stage 4 (overgrowth of fibrocartilage) and stage 5 (even coverage of fibrocartilage). The 'immature' regeneration group showed no repair or partial coverage with fibrocartilaginous tissue and the 'mature' regeneration group showed total coverage.

#### ANTIBODIES

Mouse monoclonal antibodies to human type I and type II collagen were purchased from Fuji Chemical Industries, Ltd (Toyama, Japan). The monospecificity of the antigens were checked by established western blotting<sup>21</sup>. Rabbit monoclonal antibody to human pCOL-II-C was prepared by Teijin Iwakuni Research Center (Yamaguchi, Japan), using a method proposed by Shinmei *et al.*<sup>10</sup>. The antigen was also tested for specificity to human and bovine pCOL-II-C by an established EIA<sup>10</sup>, confirming no cross reactivity with type II collagen.

#### IMMUNOLocalIZATION OF TYPE I, TYPE II COLLAGEN AND PCOL-II-C

Tissue sections were first incubated for 10 min at 37°C and then deparaffinized. After three 5-min washes in phosphate-buffered saline (PBS), hyaluronidase (Type II, H2126, SIGMA; 1 mg/ml in PBS), which was derived from sheep testis, was used for tissue permeation for 30 min. Then, endogenous peroxidase activity was blocked by 30-min treatment with 0.03% hydrogen peroxide. Further washing as mentioned above was performed, and non-specific background staining was blocked by 20-min incubation with normal horse serum for type I, type II collagen (diluted 1:66; Vector Laboratories Inc., California, U.S.A.) and normal goat serum for pCOL-II-C (diluted 1:66; Vector Laboratories). Excess serum was blotted from sections, followed by incubation for 30 min with antihuman type I, type II collagen (10 µg/ml in PBS containing 0.1% bovine serum albumin) and antihuman pCOL-II-C (18 µg/ml). The sections were rinsed with PBS and incubated for 30 min with biotinylated, affinity-purified antimouse IgG (diluted 1:200; Vector Laboratories) for type I, type II collagen and antirabbit IgG (diluted 1:200; Vector Laboratories) for pCOL-II-C. Each slide was washed with PBS and incubated with epitope-localized avidin-biotin-peroxidase complex (Vector Laboratories) for 30 min. Localization of peroxidase in tissue sections was developed with 0.03% diaminobenzidine tetrahydrochloride (DAB) in 50 mM Tris-HCl, pH 7.6, containing 0.006% hydrogen peroxide until desirable stain intensity was obtained. Finally, sections were rinsed in tap water and counterstained with Harris' hematoxylin.

#### HISTOLOGICAL ASSESSMENT

Immunolocalization of type I, type II collagen and pCOL-II-C was investigated, and especially, the grade of pCOL-II-C immunostaining was assessed using the grading system proposed by Okada *et al.*<sup>23</sup>. Briefly, the percentage of immunoreactive chondrocytes was graded as 0 to 4 as follows: grade 0 represented no staining; grade 1, <10%; grade 2, 10 to 30%; grade 3, 30 to 50%; grade 4, >50%.

Tissue sections were also scored according to the histological grading of articular cartilage repair described by Pineda *et al.*<sup>23</sup>. The scale consists of four categories: percent filling of the defect, reconstruction of the osteochondral junction, matrix staining and cell morphology, with a score from 0 (best) to 14 (worst). Safranin O staining was employed to assess the articular cartilage repair as described in the original article. Specimens were assessed at magnification of ×40 and ×100.

#### STATISTICAL ANALYSIS

Statistical analysis of differences between the two groups was carried out using Wilcoxon's rank-sum test. Data values were expressed as mean±s.d. in each group, and *P* values less than 0.05 were considered to be statistically significant. Regression lines were calculated by the method of least squares; *r* was the correlation coefficient.

## Results

#### INTRAARTICULAR ASSESSMENT

With respect to the macroscopic cartilage degeneration grading at initial osteotomy, two knees had grade 3, three had grade 4-a, four had grade 4-b, 13 had grade 4-c and two had grade 5-a. Observation following arthrotomy at plate removal showed cartilage regeneration in all cases as follows: four knees had stage 2 regeneration, seven stage 3, four stage 4, and nine stage 5 according to cartilage regeneration staging (Table II).

#### SYNOVIAL FLUID PCOL-II-C

The concentration of synovial fluid pCOL-II-C was higher in the 'immature' regeneration group (5.9±1.5 ng/ml; 11 specimens) than in the 'mature' regeneration group (2.7±1.3 ng/ml; 13 specimens) (*P*<0.01). These two values were still higher than that of control subjects (1.2±0.7 ng/ml; seven specimens) (*P*<0.05). The results suggested that type II collagen biosynthesis by chondrocytes decreased with the maturation of regenerated articular cartilage.

An additional study of 34 patients (41 knees) with OA who underwent HTO revealed that the concentration of synovial fluid pCOL-II-C according to the macroscopic cartilage degeneration grading was 5.3±1.0 ng/ml for grade 2 (four knees), 7.9±2.4 for grade 3 (six knees), 9.3±3.8 for grade 4-a (four knees), 7.2±0.8 for grade 4-b (three knees), 5.2±1.6 for grade 4-c (19 knees), and 3.9±0.8 for grade 5-a (five knees).

#### IMMUNOLocalIZATION OF TYPE I COLLAGEN

All biopsy specimens were initially stained with type I collagen to demonstrate 'regenerated cartilage' effectively contains type I collagen which fibrocartilages contain.

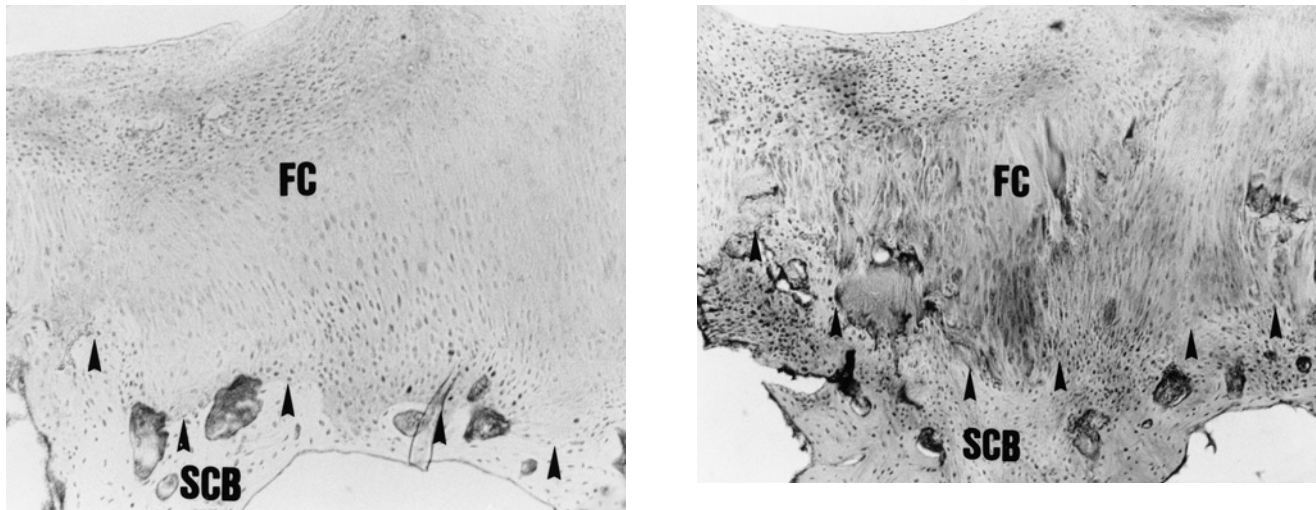


Fig. 2. Photomicrographs of serial sagittal sections of biopsy specimen. Type I collagen staining is applied to demonstrate 'regenerated cartilage' effectively contains type I collagen which fibrocartilage contain. FC: fibrocartilaginous cells, SCB: subchondral bone, Arrows: osteochondral junction. (a) Control staining which was challenged without primary antibody to type I collagen shows no positive immunostaining ( $\times 40$ ). (b) Type I collagen immunostaining. Positive type I collagen staining is detected in a subchondral bone as well as in fibrocartilage ( $\times 40$ ).

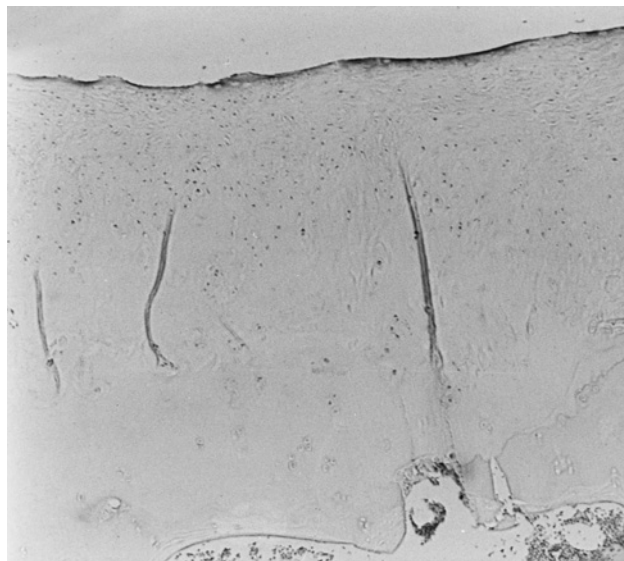

Fig. 3. Photomicrograph of normal control cartilage with pCOL-II-C staining. No immunostaining is seen in chondrocyte or the extracellular matrix ( $\times 40$ ).

Representative sample showed positive type I collagen staining in a subchondral bone as well as in fibrocartilage (Fig. 2).

#### NORMAL CONTROL CARTILAGE

Normal healthy cartilage obtained from amputated limbs with ischemic necrosis did not react positively when challenged with pCOL-II-C (Fig. 3).

#### 'IMMATURE' REGENERATION GROUP

Regenerated articular cartilage macroscopically classified into the 'immature' regeneration group was found to

contain residual degenerated cartilage with a distinct boundary in nine of 11 specimens examined. Chondrocytes strongly immunoreactive for type II collagen and pCOL-II-C were found in the superficial layer of the remaining degenerated cartilage, whose surface was fibrillated and proteoglycans was moderately depleted in eight of 11 specimens. Positive immunostaining for type II collagen was observed around chondrocyte clusters located in the middle to deep layers of the residual degenerated cartilage, whereas no chondrocytes immunoreactive for pCOL-II-C were detected in nine of 11 specimens. Slightly positive type II collagen and pCOL-II-C staining was detected around fibrillations, fissures, osteophytes and chondrocyte clusters in all specimens.

With respect to the regenerated articular cartilage, however, the surface of reparative tissue was smooth, with slightly depleted toluidine blue staining. Spindle-shaped fibrocartilaginous cells located in the superficial layer were not stained with type II collagen or pCOL-II-C in the current study (12 of 13 specimens). Instead, immunodetection of type II collagen and pCOL-II-C revealed weak immunostaining mainly around the clusters of round hyaline cartilaginous cells located in the middle to deep layers in eight of 13 specimens. These cartilaginous cells seemed to regenerate from eburnated subchondral bone, whose osteochondral junction showed marked immunostaining, and to proliferate toward the upper layers (Fig. 4).

Apart from slight background staining, each control section when challenged with non-immune mouse and rabbit IgG in place of the primary antibody consistently gave negative results.

#### 'MATURE' REGENERATION GROUP

In the current study, sections from the 'mature' regeneration group showed a different staining pattern and distribution of type II collagen and pCOL-II-C compared with the 'immature' regeneration group. Histological study demonstrated spindle-shaped fibrocartilaginous cells in the superficial to middle layers of the regenerated cartilage, where

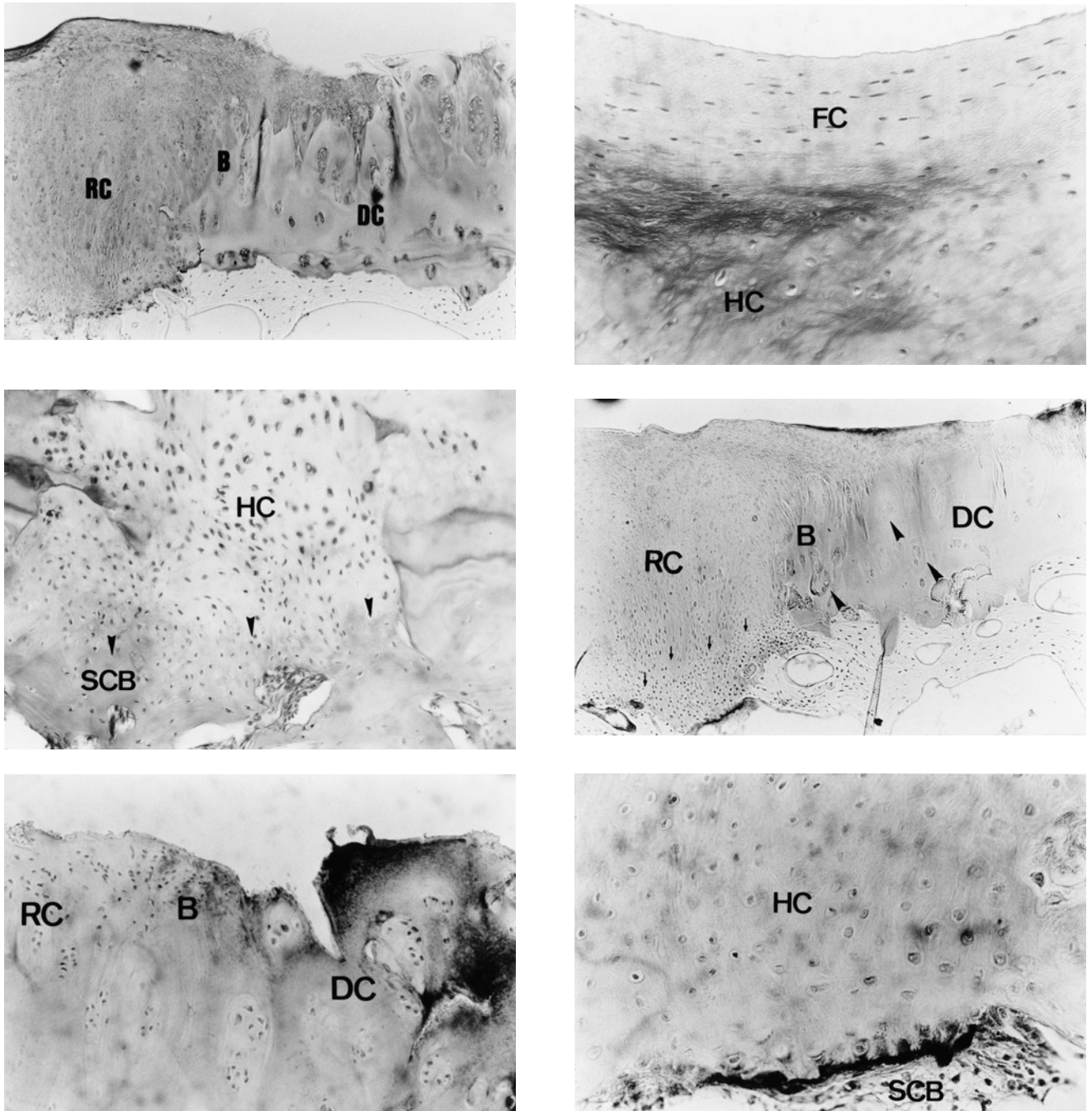


Fig. 4. Photomicrographs of serial sagittal sections of regenerated articular cartilage classified macroscopically into the 'immature' regeneration group (stage 3). These sections show a histological grading score of 4 points, and the grade of pCOL-II-C immunostaining is 3. (a) Toluidine blue staining. A distinctive boundary (B) between the remaining degenerated cartilage (DC) and regenerated cartilage (RC) is observed in all layers. Note the surface of the residual degenerated cartilage is fibrillated and proteoglycans is slightly depleted, but the surface of the regenerated cartilage is smooth ( $\times 40$ ). (b) Safranin O staining. Spindle-shaped fibrocartilaginous cells (FC) are observed in the superficial layer, and round hyaline cartilaginous cells (HC) in the middle to deep layers of the regenerated articular cartilage ( $\times 100$ ). (c) Safranin O staining. Round hyaline cartilaginous cells (HC) are observed in the middle to deep layers of the regenerated articular cartilage. Note these cartilaginous cells located in the deep layer seem to regenerate around the eburnated subchondral bone (SCB) and proliferate toward the upper layers ( $\times 100$ ). Arrows: osteochondral junction. (d) Type II collagen immunostaining. Type II collagen immunostaining is intensively positive in the superficial layer, and moderately positive around chondrocyte clusters (large arrows) located in the middle to deep layers of the remaining degenerated cartilage (DC). With respect to the regenerated cartilage (RC), intense immunostaining is detected at osteochondral junction and weak immunostaining is observed chiefly around the clusters of hyaline cartilaginous cells located in the middle to deep layers (small arrows) ( $\times 40$ ). B: boundary. (e) pCOL-II-C immunostaining. Marked pCOL-II-C immunostaining is observed in the superficial to middle layers, but not in the deep layer of the remaining degenerated cartilage (DC) ( $\times 100$ ). RC: regenerated cartilage, B: boundary. (f) pCOL-II-C immunostaining. Strong immunostaining is detected at osteochondral junction and weak immunostaining is observed around hyaline cartilaginous cells (HC) in the middle to deep layers of the regenerated cartilage ( $\times 100$ ). SCB: subchondral bone.

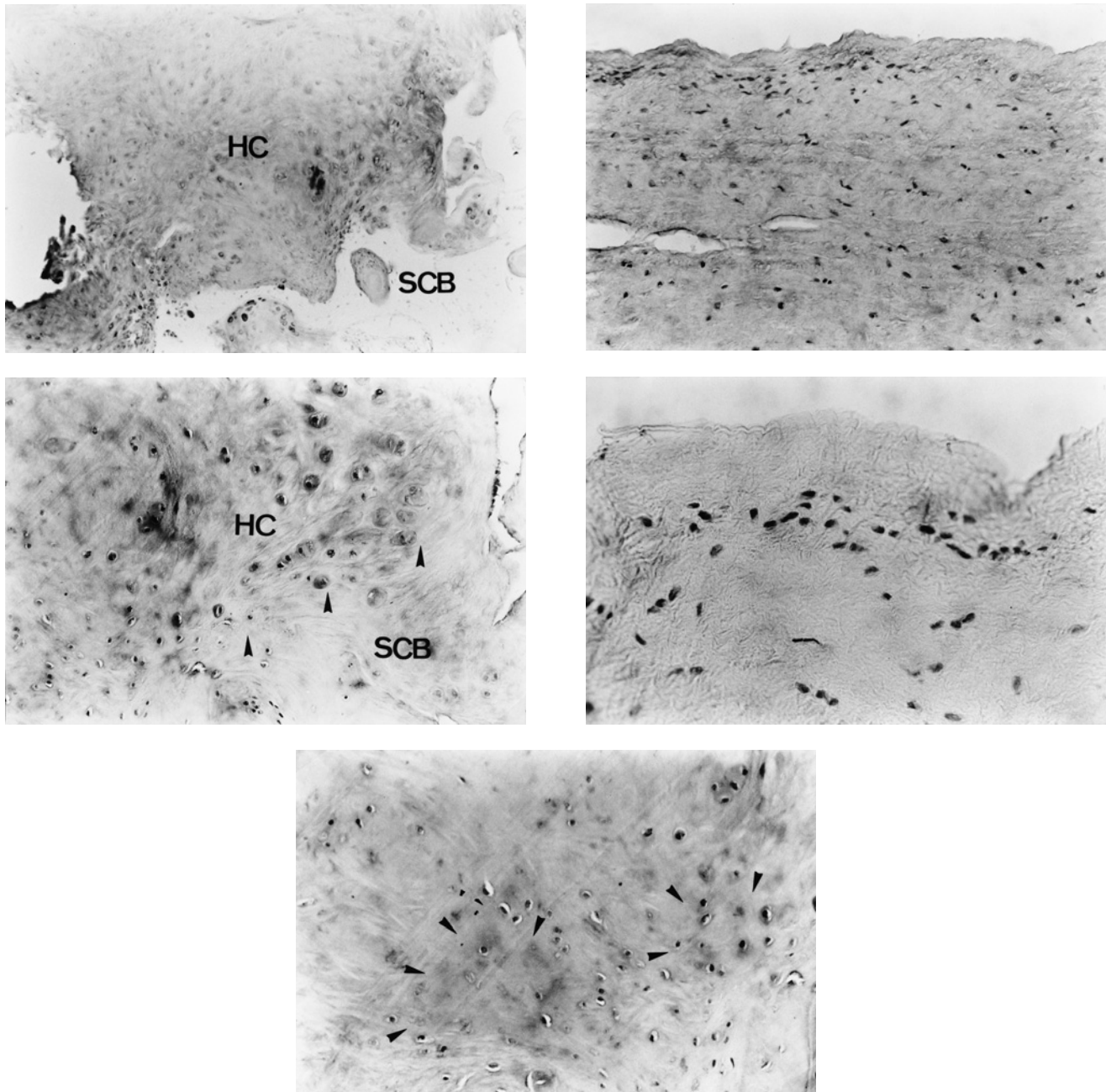


Fig. 5. Photomicrographs of serial sagittal sections of regenerated articular cartilages classified macroscopically into the 'mature' regeneration group (stage 5). These sections show a histological grading score of 3 points, and the grade of pCOL-II-C immunostaining is 2. FC: fibrocartilaginous cells, HC: hyaline cartilaginous cells; SCB: subchondral bone. (a) Toluidine blue staining. Thick regenerated articular cartilage is observed, whose superficial to middle layers show moderate proteoglycans depletion ( $\times 40$ ). (b) Safranin O staining. Spindle-shaped fibrocartilaginous cells are observed in the superficial to middle layers of the regenerated articular cartilage ( $\times 100$ ). (c) Safranin O staining. Round hyaline cartilaginous cell (HC) clusters are found scattered in the deep layer of the regenerated articular cartilage. Note that the previously eburnated subchondral bone (SCB) is filled with newly formed cancellous bone and appears to show good integration with reparative tissue at the osteochondral junction (arrows) ( $\times 100$ ). (d) pCOL-II-C immunostaining. Few fibrocartilaginous cells located in the superficial to middle layers were stained with pCOL-II-C ( $\times 100$ ). (e) pCOL-II-C immunostaining. Weakly positive staining is observed around hyaline cartilaginous cell clusters (arrows) located in the deep layer of the regenerated articular cartilage ( $\times 100$ ).

proteoglycans was moderately depleted. In 12 of 13 specimens examined, few fibrocartilaginous cells stained for type II collagen and pCOL-II-C. In four of 13 specimens, however, slight immunostaining was detected, where the surface of the reparative tissue was fibrillated.

In contrast, clusters of round hyaline cartilaginous cells were found scattered in the deep layer, whose periphery

showed weak type II collagen and pCOL-II-C staining in eight of 13 specimens. This positive immunostaining was not as prominent as that observed in the 'immature' regeneration group. In all specimens, previously eburnated subchondral bone was filled with newly formed cancellous bone and appeared to show impressive integration with reparative tissue at the osteochondral junction (Fig. 5).

Table III

Summary of the concentration of synovial pCOL-II-C, the grade of immunostaining and the histological grading score at each regeneration group

	Immature	Mature
Concentration of pCOL-II-C	*5.9±1.5	2.7±1.3
Grade of immunostaining	*2.7±0.4	1.6±0.8
Histological grading score	†5.1±1.6	3.4±0.9

Values are expressed as the mean±s.d. in each group.

\* $P < 0.01$  vs the 'Mature' regeneration group.

† $P < 0.05$  vs the 'Mature' regeneration group.

#### SEMI-QUANTITATIVE ANALYSIS

There was a positive linear correlation between the grade of immunostaining and the concentration of synovial fluid pCOL-II-C ( $r=0.652$ ;  $P < 0.001$ ). Similarly, a positive linear correlation was seen between the grade of immunostaining and the histological grading score ( $r=0.683$ ;  $P < 0.001$ ).

The concentration of synovial pCOL-II-C (5.9±1.5 vs 2.7±1.3), the grade of immunostaining (2.7±0.4 vs 1.6±0.8), and the histological grading score (5.1±1.6 vs 3.4±0.9) were significantly higher in the 'immature' regeneration group than in the 'mature' regeneration group, as shown in Table III.

#### Discussion

Recently, synovial fluid pCOL-II-C was proven to be a good marker of increased biosynthesis of type II collagen by chondrocytes, which reflected the condition of the articular cartilage with osteoarthritis<sup>10,12</sup>. pCOL-II-C is the carboxy-terminal component of type II procollagen, which is removed by a specific procollagen peptidase in the extracellular matrix and then secreted into synovial fluid<sup>9</sup>. This component was first called chondrocalcin, but was found to be immunologically identical to pCOL-II-C<sup>24</sup>. According to an *in vivo* study of Nelson *et al.*<sup>12</sup>, release of pCOL-II-C from osteoarthritic cartilage was correlated directly with total cartilage amount as well as type II collagen content. However, increased pCOL-II-C biosynthesis in osteoarthritic cartilage was not reflected in serum, where a significant reduction was observed. Shinmei *et al.*<sup>10</sup> reported that in patients with OA of the knee, the concentration of synovial fluid pCOL-II-C measured by sandwich EIA increased in accordance with the radiographic grade.

Our immunolocalization study demonstrated that the grade of pCOL-II-C immunostaining showed a significant correlation with the concentration of synovial fluid pCOL-II-C and the histological grading score. The concentration of synovial fluid pCOL-II-C was higher in the 'immature' regeneration group than in the 'mature' regeneration group, indicating decreased type II collagen biosynthesis in the regenerated articular cartilage in the 'mature' regeneration group. This was consistent with the result that the grade of immunostaining decreased in accordance with the maturation of regenerated articular cartilage. Especially, macroscopically overgrown cartilage hardly stained for pCOL-II-C. Interestingly, our findings are similar to those of Kosakai *et al.*<sup>25,26</sup>, who demonstrated an increase of synovial fluid pCOL-II-C when the patient's condition worsened and a decrease when it ameliorated. The mechanism

by which pCOL-II-C is secreted into the synovial fluid is not clear. However, the higher level of synovial fluid pCOL-II-C in the 'immature' regeneration group might be caused by residual degenerated cartilage, whose surface showed intense pCOL-II-C staining (stimulated turnover of type II collagen).

Nakajima *et al.*<sup>11</sup>, who demonstrated the immunolocalization of pCOL-II-C in articular cartilage obtained from patients with OA, RA and control subjects, pointed out that pCOL-II-C was localized in the superficial to middle layers of slightly degenerated cartilage and in all layers of moderately degenerated cartilage. Conversely, less immunostaining was observed in severely degenerated cartilage. They reported that the grade of pCOL-II-C staining showed a direct correlation with Mankin's histological-histochemical score<sup>27</sup> in slightly to moderately degenerated cartilage (Mankin's score 0 to 7) and an inverse correlation in severely degenerated cartilage (8 to 14). In contrast, the present study revealed that the concentration of synovial fluid pCOL-II-C increased in accordance with the macroscopic cartilage degeneration grade, and was highest in grade 4-a (erosion of articular cartilage surface), then decreased with exposure or destruction of the subchondral bone. With all these facts taken into consideration, increased type II collagen biosynthesis in the regenerated articular cartilage as well as degenerated cartilage, could be confirmed by determining the type of pCOL-II-C staining pattern, which also had a positive linear correlation with synovial fluid pCOL-II-C concentration. By means of minimally invasive puncture and aspiration of the knee joint, measurement of synovial fluid pCOL-II-C could help to evaluate the intraarticular condition of the knee joint before and after mechanical treatment by HTO.

Currently, many investigators are exploring various methods to improve the healing of full or partial-thickness defects in the articular cartilage in experimental animals<sup>28-36</sup>. They adopted transplantation of cultured mesenchymal stem cells<sup>30,36</sup>, gel-chondrocyte composite<sup>32,35</sup>, isolated chondrocytes<sup>28,31</sup> or periosteal membrane<sup>33,34</sup>, growth factors<sup>29</sup>, and others. They reported qualitative and quantitative changes in the reparative tissues when the animals were sacrificed from 1 day to 12 months after surgery. Other investigators reported that the reparative tissues initially resembled hyaline-like cartilage, developed extensive degenerative changes and matured into a fibrotic appearing scar<sup>37-39</sup>. Along these lines, there have been a number of attempts to establish procedures for articular cartilage repair, many of which are not clinically useful at the present time.

At our institution, however, we recruited elderly human subjects with OA of the knee who had previously undergone HTO and achieved a good clinical outcome post-operatively. Especially, articular cartilage defects in human knees with OA are much larger than those in small experimental animals. Thus, the cartilage defects in elderly human knees might show somewhat different cartilage repair compared with that in previously established reports of experimental animals. The authors believe that relief of knee pain depends greatly on the coverage of previously degenerated portions of the articular cartilage by fibrocartilage<sup>3,20</sup>. Unsatisfactory clinical results were due to under-correction of the varus deformity, with post-operative femoro-tibial angle of more than 180°. Though the present study failed to recruit patients with poor post-operative results, we firmly believe that there will be no or less regeneration in the knees with under-correction of the varus deformity.

In conclusion, we examined the relation between pCOL-II-C staining pattern and the level of synovial fluid pCOL-II-C at different stage of cartilage regeneration, and found that the immunostaining and synovial fluid concentration of pCOL-II-C decreased in accordance with the progression of articular cartilage regeneration observed after surgical treatment by HTO. Further studies are required, and this study accounts for only one aspect of type II collagen turnover in cartilage regeneration of the human knee.

## References

- Jackson JP, Waugh W. Tibial osteotomy for osteoarthritis of the knee. *J Bone Joint Surg* 1961;43-B:746-51.
- Bauer GCH, Insall J, Koshino T. Tibial osteotomy in gonarthrosis (osteoarthritis of the knee). *J Bone Joint Surg* 1969;51-A:1545-63.
- Koshino T, Tsuchiya K. The effect of high tibial osteotomy on osteoarthritis of the knee. Clinical and histological observations. *Int Orthop (SICOT)* 1979; 3:37-45.
- Koshino T, Takahashi S, Suzuki K, Shimizu H. Regeneration of degenerated articular cartilage in the knee with osteoarthritis after high tibial osteotomy. Report of two cases. *Yokohama Med Bull* 1992;42:119-25.
- Buckwalter JA, Mow VC, Ratcliffe A. Restoration of injured or degenerated articular cartilage. *J Am Acad Orthop Surg* 1994;2:192-201.
- Mayne R. Cartilage collagens. What is their function, and they invoked in articular disease? *Arthritis Rheum* 1989;32:241-6.
- Wada S, Koshino T, Saito T, Takagi T, Yoshida T, Murase T. Regenerative changes of degenerated articular cartilage after high tibial osteotomy for osteoarthritis of the knee (Abstract). *Comb Orthop Res Soc (Hamamatsu) (Suppl)* 1998;326.
- Choi HU, Tang LH, Johnson TL. Isolation and characterization of a 35000 molecular weight subunit fetal cartilage matrix protein. *J Biol Chem* 1983;258: 655-61.
- Poole AR, Pidoux I, Reiner A. Association of an extracellular protein (chondrocalcin) with the calcification of cartilage in endochondral bone formation. *J Cell Biol* 1984;98:54-65.
- Shinmei M, Ito K, Matsuyama S. Joint fluid carboxy-terminal type II procollagen peptide as a marker of cartilage collagen biosynthesis. *Osteoarthritis Cart* 1993;1:121-8.
- Nakajima H, Shinmei M, Ito K, Matsuyama S, Kikuchi T, Honda H. Localization of carboxy-terminal type II procollagen peptide (pCOL-II-C) in diseased cartilage. *J Orthop Sci* 1997;2:229-38.
- Nelson F, Dahlberg L, Laverty S, Reiner A, Pidoux I, Ionescu M, *et al.* Evidence for altered system of type II collagen in patients with osteoarthritis. *J Clin Invest* 1998;102:2115-25.
- Alini M, Matsui Y, Dodge GR, Poole AR. The extracellular matrix of cartilage in the growth plate before and during calcification: changes in the composition and degradation of type II collagen. *Calcif Tissue Int* 1992;50:327-35.
- Masson B, Carey D, Alini M, Ionescu M, Rosenberg LC, Poole AR, *et al.* Cartilage and bone metabolism in rheumatoid arthritis. Difference between rapid and slow progression of disease identified by serum marker of cartilage metabolism. *J Clin Invest* 1995; 95:1071-7.
- Kujawa MJ, Weitzhandler M, Poole AR, Rosenberg LC, Caplan AI. Association of the C-propeptide of type II collagen with mineralization of embryonic chick long bone and sternal development. *Connect Tissue Res* 1989;23:179-99.
- Lee ER, Matsui Y, Poole AR. Immunocytochemical and immunocytochemical studies of the C-propeptide of type II procollagen in chondrocytes of the growth plate. *J Histochem Cytochem* 1990;38:659-93.
- Spanheimer RG, Bird TA, Peterkofsky B. Regulation of collagen synthesis and mRNA levels in articular cartilage of scorbutic guinea pigs. *Arch Biochem Biophys* 1986;246:33-41.
- Koshino T, Machida J. Grading system of articular cartilage degeneration in osteoarthritis of the knee. *Bull Hosp J Dis* 1993;53:41-6.
- Outerbridge RE. The etiology of chondromalacia patellae. *J Bone Joint Surg* 1961;43-B:752-7.
- Koshino T, Morii T, Wada J, Saito H, Ozawa N, Noyori K. High tibial osteotomy with fixation by a blade plate for medial compartment osteoarthritis of the knee. *Orthop Clin North Am* 1989;20:227-43.
- Burgeson RE, Hollister DW. Collagen heterogeneity in human cartilage. Identification of several new collagen chains. *Biochem Biophys Res Commun* 1979; 87:1124-31.
- Okada Y, Shinmei M, Tanaka O, Naka K, Kimura A, Nakanishi I, *et al.* Localization of matrix metalloproteinase 3 (stromelysin) in osteoarthritic cartilage and synovium. *Lab Invest* 1992;66:680-90.
- Pineda S, Pollack A, Stevenson S, Goldberg V, Caplan A. A semiquantitative scale for histologic grading of articular cartilage repair. *Acta Anat* 1992;143:335-40.
- van der Rest M, Rosenberg LC, Olsen BR. Chondrocalcin is identical with the C-propeptide of type II procollagen. *Biochem J* 1985;237:923-5.
- Kosakai O, Shindoh K, Onozawa T, Yamaga S. Evaluation of the chondrocalcin in synovial fluids of the knee (in Japanese). *Hokkaido J Orthop Traumatol* 1995;38:75-8.
- Kosakai O, Shitoto K, Arai Y, Akimoto T, Maruyama Y, Yamauchi Y. Evaluation of the chondrocalcin in synovial fluids from the knee with hyarthrosis (in Japanese). *Kanto J Orthop Traumatol* 1996;27: 135-9.
- Mankin HJ, Dorfman H, Lippiello L, Zarins A. Biochemical and metabolic abnormalities in articular cartilage from osteoarthritic human hips. *J Bone Joint Surg* 1971;53-A:523-37.
- Grande DA, Pitman MI, Peterson L, Menche D, Klein M. The repair of experimentally produced defects in rabbit articular cartilage by autologous chondrocyte transplantation. *J Orthop Res* 1989;7:208-18.
- Hunziker EB. Growth-factor-induced healing of partial-thickness defects in adult articular cartilage. *Osteoarthritis Cart* 2001;9:22-32.
- Im GI, Kim DY, Shin JH, Hyun CW, Cho WH. Repair of cartilage defects the rabbit with cultured mesenchymal stem cells from bone marrow. *J Bone Joint Surg* 2001;83-B:289-94.
- Itay S, Abramovici A, Nevo Z. Use of cultured embryonal chick epiphyseal chondrocytes as grafts for defects in chick articular cartilage. *Clin Orthop* 1987;220:284-303.



32. Kawamura S, Wakitani S, Kimura T, Maeda A, Caplan AI, Shino K, *et al.* Articular cartilage repair. Rabbit experiments with a collagen gel-biomatrix and chondrocytes cultured in it. *Acta Orthop Scand* 1998;69:56–62.
33. O'Driscoll SW, Keeley FW, Salter RB. The chondrogenic potential of free autogenous periosteal grafts for biological resurfacing major full-thickness defects in joint surfaces under the influence of continuous passive motion. An experimental investigation in the rabbit. *J Bone Joint Surg* 1986;68-A:1017–35.
34. O'Driscoll SW, Keeley FW, Salter RB. Durability of regenerated articular cartilage produced by free autogenous periosteal grafts in major full-thickness defects in joint surfaces under the influence of continuous passive motion. A follow-up report at one year. *J Bone Joint Surg* 1988;70-A:595–606.
35. Wakitani S, Kimura T, Hirooka A, Ochi T, Yoneda M, Yasui N, *et al.* Repair of rabbit articular surfaces with allograft chondrocytes embedded in collagen gel. *J Bone Joint Surg* 1989;71-B:74–80.
36. Wakitani S, Goto T, Pineda S, Young RG, Mansour JM, Caplan AI, *et al.* Mesenchymal cell-based repair of large, full-thickness defects of articular cartilage. *J Bone Joint Surg* 1994;76-A:579–92.
37. Coletti JM Jr, Akeson WH, Woo SLY. A comparison of the physical behavior of normal articular cartilage and the arthroplasty surface. *J Bone Joint Surg* 1972;54-A:147–60.
38. Furukawa T, Eyre DR, Koide S, Glimcher MJ. Biochemical studies on repair cartilage resurfacing experimental defects in the rabbit knee. *J Bone Joint Surg* 1980;62-A:79–89.
39. Mitchell N, Shepard N. The resurfacing of adult rabbit articular cartilage by multiple perforations thru subchondral bone. *J Bone Joint Surg* 1976;58-A:230–3.