

# Extensor digitorum longus tenosynovitis caused by talar head impingement in an ultramarathon runner: a case report

H Kobayashi, M Sakurai

Department of Orthopaedic Surgery, Heisei Memorial Hospital, Fujieda, Shizuoka, Japan

T Kobayashi

Department of Dermatology, Atami Hospital, International University of Health and Welfare, Atami, Shizuoka, Japan

---

## ABSTRACT

Stenosing tenosynovitis of the extensor digitorum longus tendon is an injury related to ultramarathon running. A 32-year-old male ultramarathon runner developed chronic tenosynovitis of the ankle dorsiflexors. He was diagnosed with extensor digitorum longus tenosynovitis caused by talar head impingement associated with exostosis. He failed to respond to non-operative management and decided to undergo tenosynovectomy of the extensor digitorum longus tendon. The pain was relieved without functional disturbance of the foot and ankle, and the patient returned to running 3 weeks postoperatively. At the 2-year follow-up, he was participating fully in ultramarathons.

**Key words:** ankle; cumulative trauma disorders; tenosynovitis

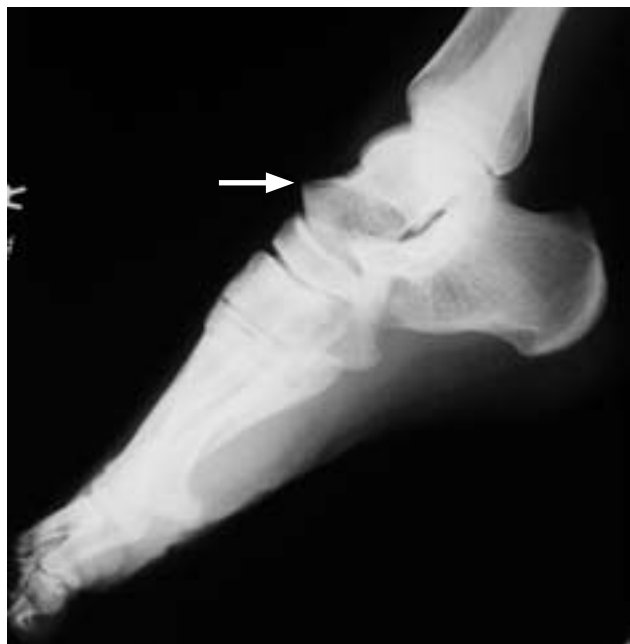---

## INTRODUCTION

Isolated stenosing tenosynovitis of the extensor digitorum longus tendon is uncommon.<sup>1</sup> Peritendinitis/tendinitis of the tendons passing under the extensor retinaculum in the ankle is a musculoskeletal injury caused by overuse, known as 'ultramarathoner's ankle'.<sup>2,3</sup> Inflammation occurs in the inferior extensor retinaculum at the anterior aspect of the ankle.<sup>2</sup> Causative factors are excessive pronation,<sup>4</sup> use of tight-fitting shoes in ischaemic conditions,<sup>2</sup> muscle imbalance,<sup>5</sup> eccentric overload,<sup>6</sup> and a typical ultramarathon (shuffling) gait.<sup>2,3</sup> Talar head impingement and exostosis appears to be a novel aetiology. We report a case of 'ultramarathoner's ankle' requiring surgery.

## CASE REPORT

In June 1999, a 32-year-old man developed swelling and pain in his right ankle after finishing a 100-km



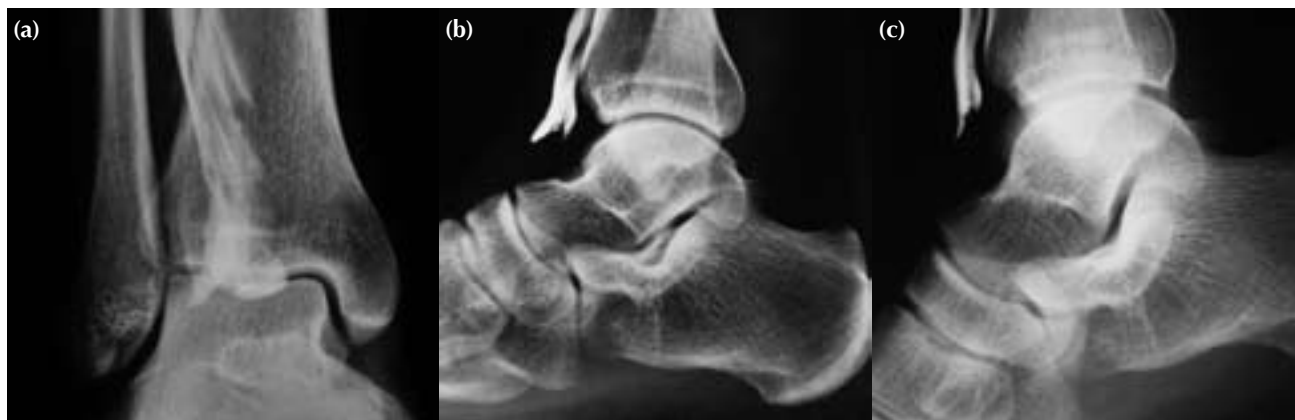**Figure 1** Lateral stress radiograph taken at maximum plantar flexion showing the dorsal thrust of the talar head at the talonavicular joint (arrow).

ultramarathon. The patient was an elite amateur runner, with a monthly training distance of 550 km and a best marathon time of 2.52 hours. He was diagnosed with acute tenosynovitis of the ankle dorsiflexors and was treated conservatively. Crepitation and triggering remained for more than 3 years and were exacerbated by intensive training. He did not respond to conservative treatment including oral non-steroidal anti-inflammatory drugs, taping, cast immobilisation, a functional orthotic insole, and

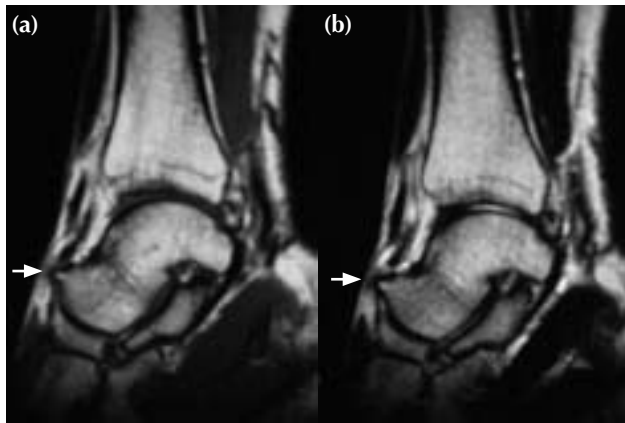
injected corticosteroids.

The patient was referred to us in April 2003. Physical examination revealed tenderness and swelling over the dorsal ankle, particularly along the extensor digitorum longus tendon. Crepitation and triggering were noted at the proximal inferior extensor retinaculum. At 30° plantar flexion, the talonavicular joint was hypermobile and the extensor digitorum longus tendon was impinged on by the talar head and slipped laterally. Toe extension was slightly weak and painful. The ankle's range of movement was normal. He had no history of collagen disease or of ankle twisting. Blood data were all normal. A lateral stress radiograph taken at maximum plantar flexion confirmed the dorsal thrust of the talar head at the talonavicular joint (Fig. 1). Anteroposterior tenography revealed irregular relief of the tendon sheath with an indentation and deficiency; lateral stress tenography revealed the anterior thrust of the talar head exacerbating the tendon sheath stenosis (Fig. 2). Sagittal magnetic resonance images taken at 30° plantar flexion demonstrated that talar head exostosis was responsible for its impingement on the extensor digitorum longus tendon located above (Fig. 3). A diagnosis of 'ultramarathoner's ankle' was made and operative release of the tendon advised.

A 4-cm dorsolateral longitudinal incision was made at the talonavicular joint via an anterior approach. The inferior extensor retinaculum was attached to the extensor digitorum longus tendon. Tenolysis and excision of the talar head exostosis allowed this tendon to glide freely. No bowstringing of the tendon was seen postoperatively. The patient used crutches for the first 5 days after the operation and weight bearing was allowed as tolerated with early aggressive rehabilitation.



**Figure 2** (a) Anteroposterior tenography showing irregular relief of the tendon sheath with an indentation and deficiency. (b) Lateral tenography taken at the neutral position showing tendon sheath stenosis at the level of the talonavicular joint. (c) Lateral tenography taken at 30° plantar flexion showing the anterior thrust of the talar head exacerbating the tendon sheath stenosis.



**Figure 3** (a) T1-weighted and (b) T2-weighted sagittal magnetic resonance images taken at 30° plantar flexion showing the osteophyte of the talar head impinging on the extensor digitorum longus tendon lying directly above (arrow).

The patient had an uneventful recovery enjoying pain-free, undisturbed foot and ankle function. He returned to running 3 weeks postoperatively. At the 2-year follow-up, he was participating fully in ultramarathons.

## DISCUSSION

The most common injuries associated with ultramarathons are retropatellar pain syndrome, Achilles tendinitis, medial tibial stress syndrome, and extensor digitorum longus tenosynovitis.<sup>2,3,7</sup> Eccentric overload along with repeated irritation of the foot and ankle decelerators is the main aetiology,<sup>2,6</sup> which

is aggravated by high dorsal pressure from tight footwear.<sup>2</sup>

In our patient, talar head impingement and exostosis formed the primary aetiology. Although the ultramarathon (shuffling) gait<sup>2,3</sup> has a characteristically shortened stride and a decreased range of plantar- and dorsi-flexions, more movement occurs at the ankle than the hip or knee.<sup>8</sup> This pendulum-like movement reduces fatigue of the hip and knee muscles, but compensates for this by increasing the mechanical stress on the ankle, leading to talocalcaneonavicular ligament laxity and even talonavicular subluxation. Biomechanically, talonavicular subluxation requires extreme plantar flexion of the foot. On bumpy or downhill roads, the foot is forced to plantarflex with an anteriorly directed movement across the talonavicular joint causing the talar head to impinge on the extensor tendon. If the talonavicular joint is not surgically stabilised, the patient may develop recurrent tenosynovitis from further exostosis.<sup>9</sup>

Surgery for extensor digitorum longus tenosynovitis has been reported for torsional<sup>1</sup> and thorn injuries.<sup>10</sup> Ankle tenosynovitis may further constrict the extensor retinaculum tendon; ischaemic changes within the tendon from extrinsic pressure may cause attritional rupture of the tendon.<sup>11</sup> Conservative therapy is effective in most patients<sup>8</sup>; surgery is only indicated in recalcitrant cases with severe impairment confirmed by physical examinations and image findings. Stress tenography is useful for visualising the lesions. If tenosynovectomy is required, the distal inferior extensor retinaculum must be kept intact to avoid postoperative bowstringing of the tendon. Care should be taken to avoid damage to the superficial peroneal nerve traversing the operative site.

## REFERENCES

1. Perlman MD, Leveille D. Extensor digitorum longus stenosing tenosynovitis. A case report. *J Am Podiatr Med Assoc* 1988;78:198–9.
2. Fallon KE. Musculoskeletal injuries in the ultramarathon: the 1990 Westfield Sydney to Melbourne run. *Br J Sports Med* 1996;30:319–23.
3. Bishop GW, Fallon KE. Musculoskeletal injuries in a six-day track race: ultramarathoner's ankle. *Clin J Sport Med* 1999;9:216–20.
4. Subotnick SI. The ankle. *Sports medicine of the lower extremity*. New York: Churchill Livingstone; 1989:275–6.
5. So CH, Siu TO, Chan KM, Chin MK, Li CT. Isokinetic profile of dorsiflexors and plantar flexors of the ankle: a comparative study of elite versus untrained subjects. *Br J Sports Med* 1994;28:25–30.
6. Curwin S, Stanish WD. *Tendinitis: its aetiology and treatment*. Lexington: Collamore Press; 1984:25–8.
7. Hutson MA. Medical implications of ultra marathon running: observations on a six day track race. *Br J Sports Med* 1984;18:44–5.
8. Hawes B. Ultramarathon: a general and podiatric perspective. *Aust Podiatrist* 1990;24:7–9.
9. Cannon LB, Hackney RG. Anterior tibiotalar impingement associated with chronic ankle instability. *J Foot Ankle Surg* 2000;39:383–6.
10. Nyska M, Sperber AD, Howard CB, Nyska A, Dekel S. Ankle extensor tendon synovitis due to a date palm thorn. *Foot Ankle* 1989;10:180–3.
11. Murphy GA. Disorders of tendons and fascia. In: Canale ST, editor. *Campbell's operative orthopaedics*. Vol IV, 10th ed. Philadelphia: Mosby; 2003:4189–230.